Registration From RTT's View

Pooneh Porrangi

Introduction

- With the introduction of IMRT and SBRT we have reached a point where the radiation dose can be shaped to the target volume with steep dose gradients to surrounding normal tissues.
- These new techniques introduce an enormous inherent risk.
- ***"We are at increased risk of missing very precisely"***

Tuesday, February 2, 20XX Sample Footer Text 2

Uncertainties In IGRT

PARDISNOOR IMAGING AND CANCER CENTER

IGRT Can Not Be Able To Fix Everything

PARDISNOOR IMAGING AND CANCER CENTER

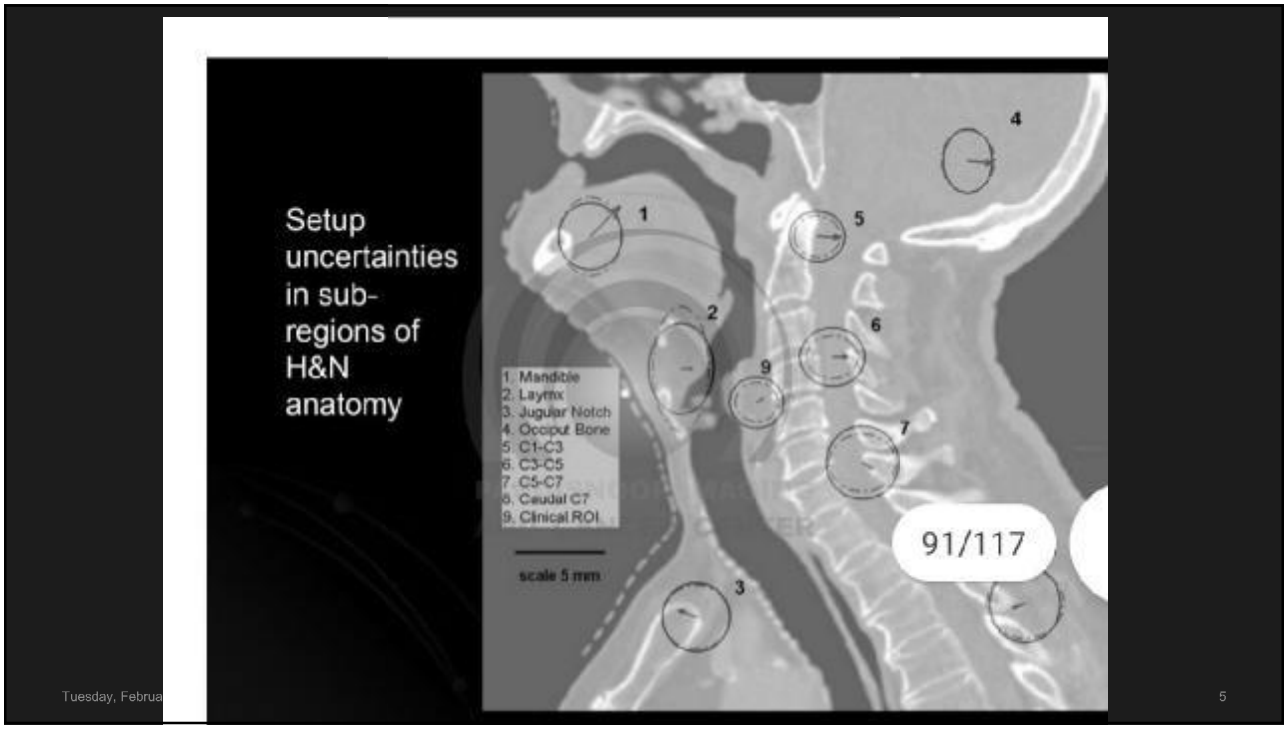
Setup uncertainties in sub-regions of H&N anatomy
1. Mandible
2. Larynx
3. Jugular Notch
4. Occiput Bone
5. C1-C3
6. C3-C5
7. C5-C7
8. Caudal C7
9. Clinical ROI
scale 5 mm
91/117
Tuesday, Februa
5

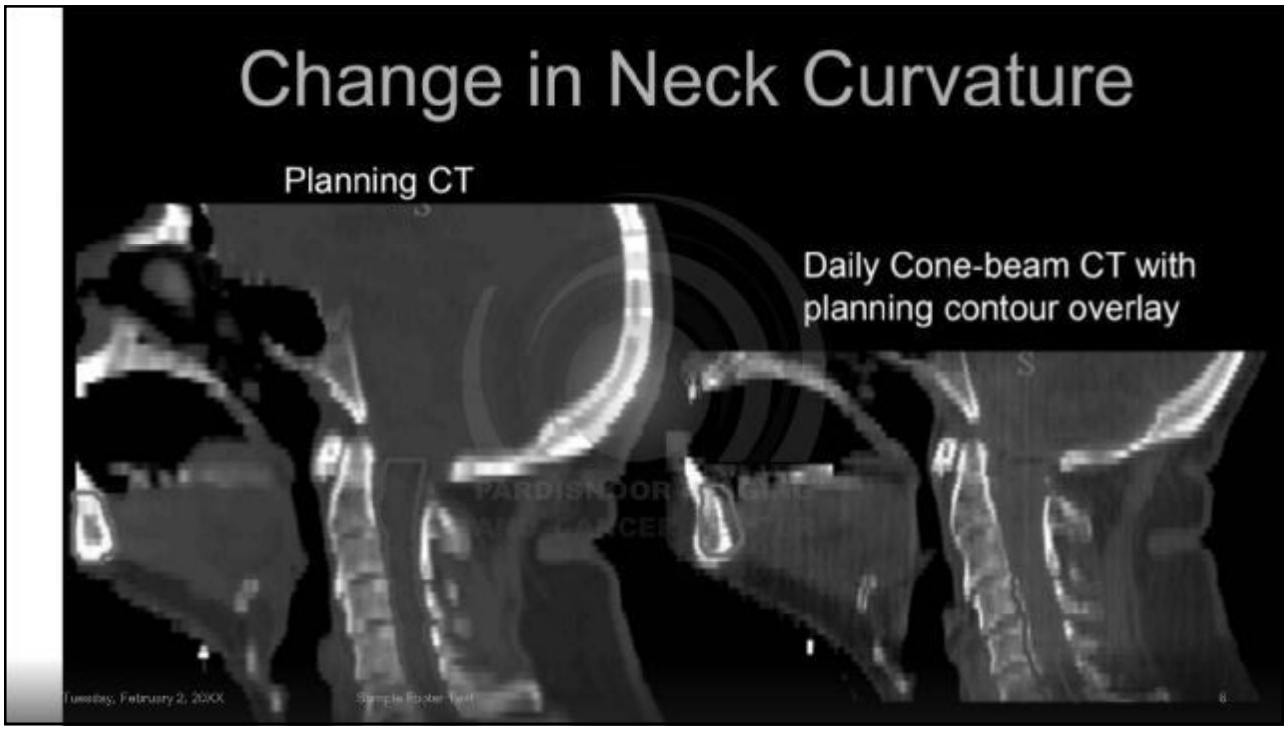
Change in Neck Curvature
Planning CT
Daily Cone-beam CT with planning contour overlay
Tuesday, February 2, 20XX
Sample Footer Text
8

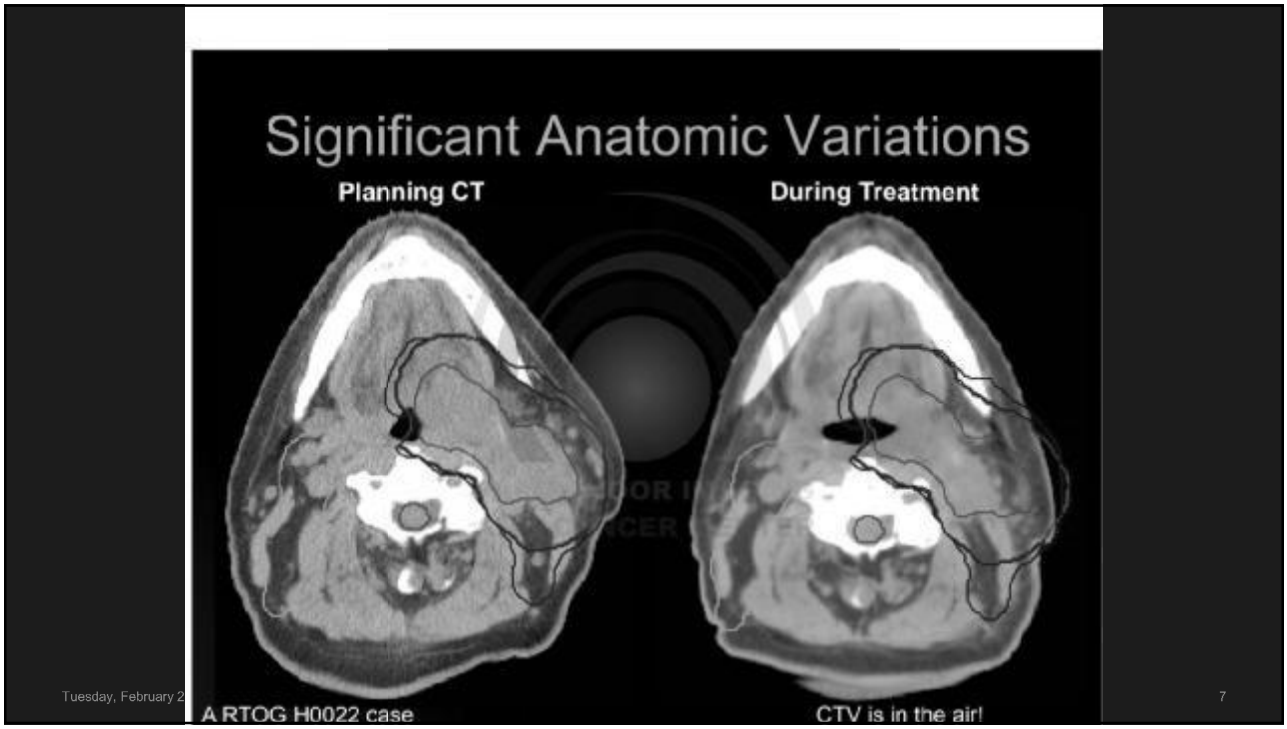
Significant Anatomic Variations
Planning CT
During Treatment
Tuesday, February 2
A RTOG H0022 case
CTV is in the air!
7

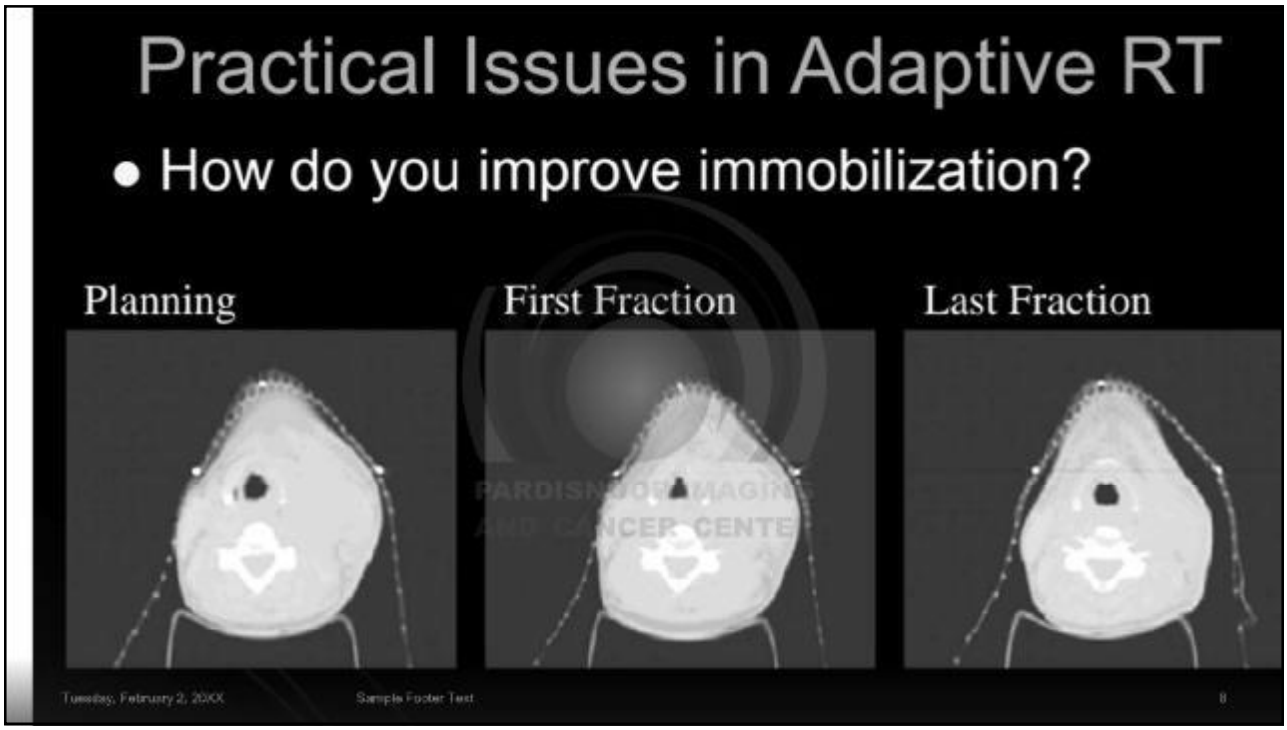
Practical Issues in Adaptive RT
• How do you improve immobilization?
Planning
First Fraction
Last Fraction
Tuesday, February 2, 20XX
Sample Footer Text
8

Aligning Bone or Soft Tissue Target?
Ref
Daily
A
A
R
L
L R
I
I
Tuesday, February 2, 20
9

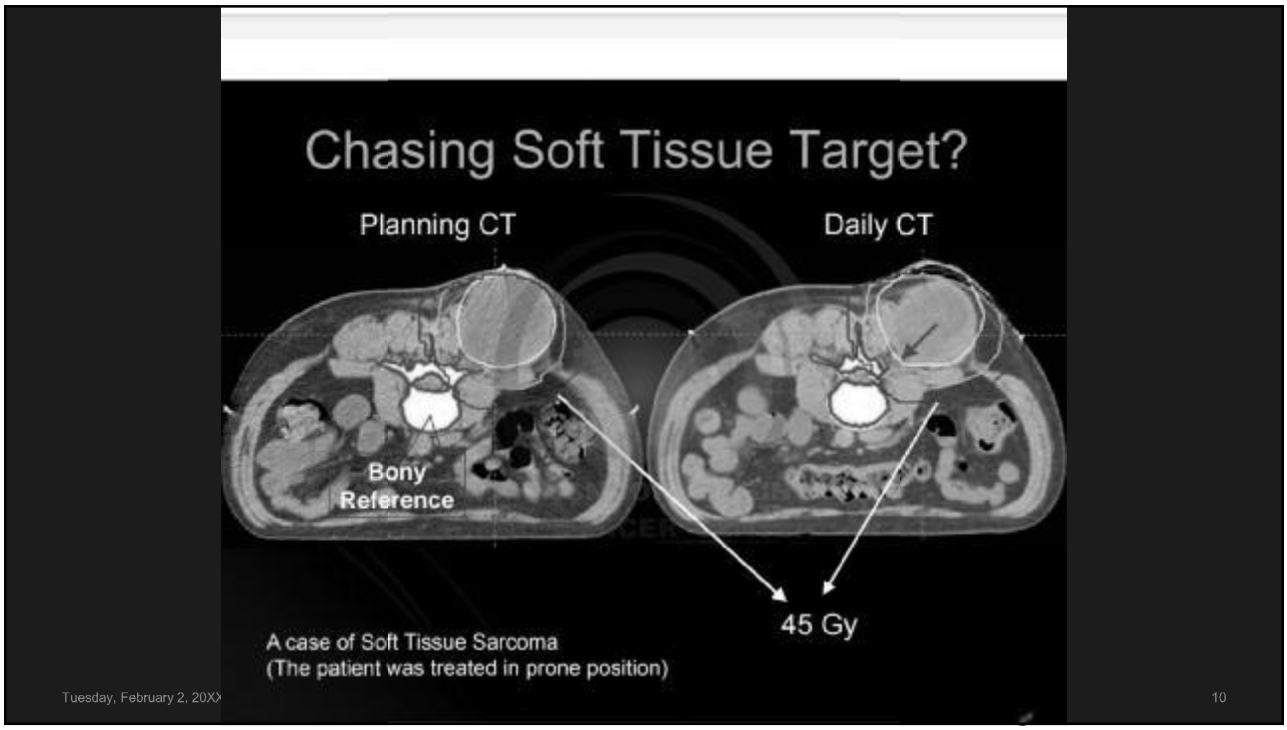
Chasing Soft Tissue Target?
Planning CT
Daily CT
Bony
Reference
45 Gy
A case of Soft Tissue Sarcoma
(The patient was treated in prone position)
Tuesday, February 2, 20X
10

Tell Us About
Your
Experiences
Tuesday, February 2, 20XX
Sample Footer Text
11

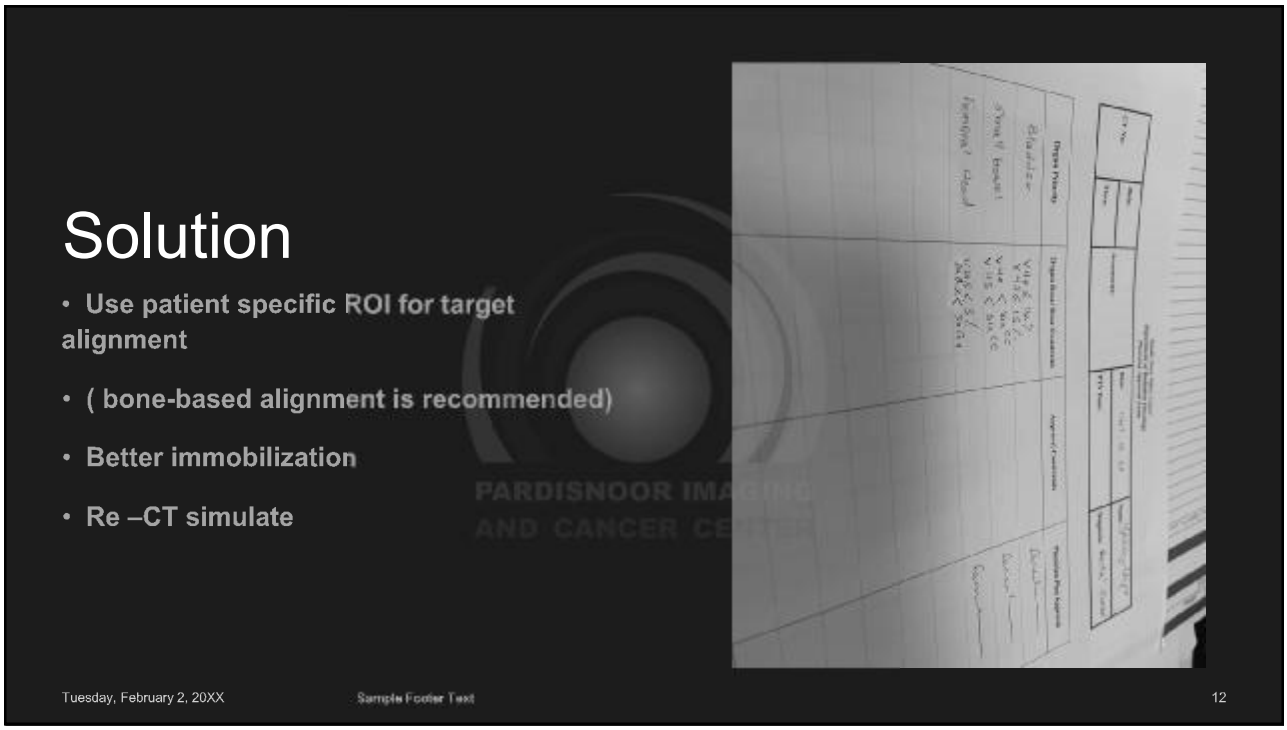
Solution
• Use patient specific ROI for target alignment
• (bone-based alignment is recommended)
• Better immobilization
• Re –CT simulate
Tuesday, February 2, 20XX
Sample Footer Text
12

Thank You
"The best way to find yourself is to lose yourself in the service of others."
—Mahatma Ghandi
PARDISNOOR IMAGING AND CANCER CENTER
Tuesday, February 2, 20XX
Sample Footer Text
13